ASIDE Case Reports

Case Report

Proximal Duodenal Obstruction After Adult Ladd Procedure Diagnosed by Endoscopy: A Case Report

Akram Alnounou[1,*], Ajay Katwala[2], Bisher Sawaf[3], Arghyadeep Ganguly[1], Yusuf Hallak[3]

1-Department of Internal Medicine, Western Michigan University, Homer Stryker M.D. School of Medicine, Kalamazoo, MI, USA
2-College of Health Sciences, Marquette University, Milwaukee, WI, USA
3-Department of Internal Medicine, University of Toledo Medical Center, Toledo, OH, USA

ARTICLE INFO

Article history:
Received 26 Mar. 2026
Received in revised form 11 Apr. 2026
Accepted 24 Apr. 2026
Published 25 Apr. 2026

Keywords:
Intestinal malrotation
Ladd procedure
Duodenal obstruction
Gastrojejunostomy
Case report
Adult

ABSTRACT

Intestinal malrotation is a congenital anomaly commonly occurring in infancy, with adult presentation being rare. The Ladd procedure is the standard treatment for symptomatic malrotation; however, postoperative complications in adults, including obstruction of the second portion of the duodenum (D2), remain poorly characterized, and their etiology may be multifactorial. A 28-year-old male with chronic gastrointestinal symptoms underwent an elective robotic-assisted laparoscopic Ladd procedure for intestinal malrotation discovered on imaging. He developed persistent high-volume bilious gastric output from postoperative day five; CT and upper GI contrast study failed to identify a transition point. Due to persistent symptoms and radiographic–clinical discordance, esophagogastroduodenoscopy was performed and revealed high-grade narrowing of the second portion of the duodenum. Reoperation revealed dense retroperitoneal fixation precluding safe duodenal mobilization; gastrojejunostomy was performed. Postoperative recovery was complicated by transient dumping syndrome, which improved with dietary modification. D2 obstruction identified early after the Ladd procedure is rare in adults but should be considered when persistent high-output gastric decompression follows surgery. Whether this obstruction was newly created by surgery or represented a pre-existing congenital abnormality unmasked postoperatively could not be determined, as no baseline assessment of duodenal patency was performed. This case illustrates the potential value of endoscopic evaluation when standard imaging and clinical findings are discordant. Follow-up was limited to two weeks, and longer-term outcome data are needed.

1. Introduction

Intestinal malrotation is a defect in the normal embryonic rotation that can cause abdominal obstruction, presenting acutely or with chronically intermittent, nonspecific gastrointestinal (GI) symptoms [1]. Intestinal malrotation is frequently misdiagnosed as functional disease (e.g., irritable bowel syndrome, peptic ulcer, pancreatic disease). Still, it must be accurately identified, as undiagnosed malrotation carries the risk of midgut volvulus and, in its absence, may cause chronic symptoms that impair quality of life [1, 2]. In older children and adults, malrotation is rarely suspected on clinical grounds and is generally first identified on imaging studies or at laparotomy [3].

Epidemiologically, intestinal malrotation is associated with congenital abnormalities and almost entirely affects pediatric populations, with 30% of cases occurring within the first month of life and 75% within the first five years [4]. Adult cases are extremely rare, accounting for only 0.2% to 0.5% of all cases [5]. The standard surgical treatment for symptomatic intestinal malrotation is the Ladd procedure, which involves division of Ladd bands, widening of the mesenteric base, positioning of the small bowel in the right abdomen and colon in the left, and appendectomy [6]. The procedure is well established in pediatric populations, where postoperative complications, including intestinal obstruction and, less commonly, recurrent midgut volvulus, have been documented [7]. In adults, however, published experience with the Ladd procedure and its postoperative complications is substantially more limited, and extrapolation from pediatric data must be made cautiously, given differences in tissue characteristics and adhesion biology [3, 6, 8].

While duodenal obstruction from Ladd bands has been described as a presenting feature of malrotation, [9] early proximal duodenal obstruction identified in the postoperative period following an adult Ladd procedure has received minimal attention. Few prior reports have detailed the diagnostic workup and individualized surgical decision-making when this clinical scenario is encountered in an adult. Here, we report early postoperative D2 obstruction following adult Ladd procedure and the diagnostic and operative approach employed.

2. Case Presentation

A 28-year-old male presented to the emergency department with four days of progressively worsening nausea, bilious vomiting, and

* Corresponding author: Akram Alnounou, Department of Internal Medicine, Western Michigan University Homer Stryker M.D. School of Medicine Kalamazoo, MI, USA. Email: akram.alnounou@wmed.edu

Published and owned by PubPorta Publishing LLC. Academic oversight and scholarly guidance are provided by the American Society for Inclusion, Diversity, and Equity in Healthcare (ASIDE). ISSN (Print) 3066-7224, ISSN (Online) 3066-7232. ©2026 The Author(s). This is an open-access article distributed under the terms of the Creative Commons Attribution 4.0 International License (CC BY 4.0). Hosting by ASIDE Journals.

Citation: Alnounou A, Katwala A, Sawaf B, Ganguly A, Hallak Y. Proximal Duodenal Obstruction After Adult Ladd Procedure Diagnosed by Endoscopy: A Case Report. ASIDE Case Reports. 2026;2(3):26-31, doi:10.71079/ASIDE.CR.042526687

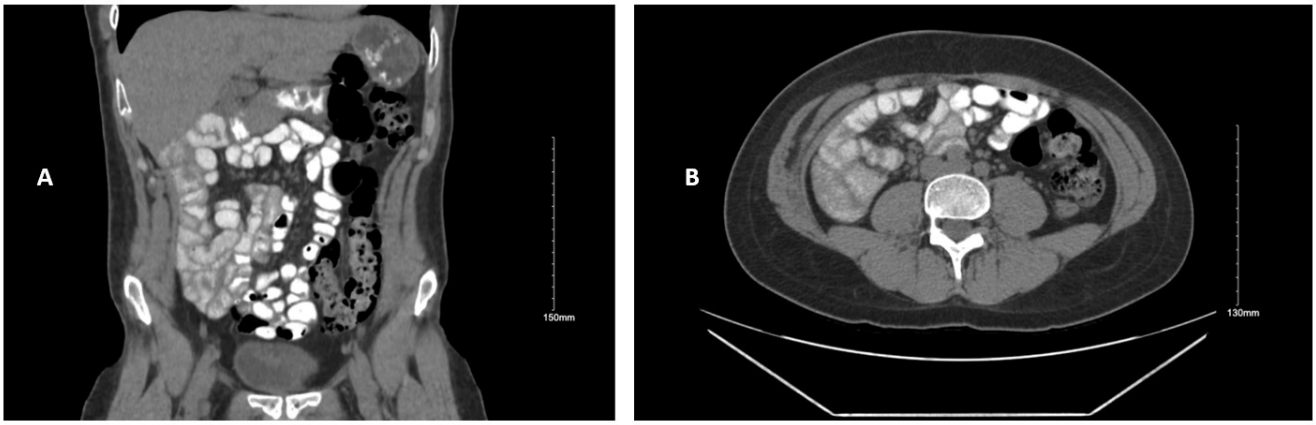

Figure 1: A. Initial coronal CT abdomen (preoperative diagnosis): Coronal CT abdomen/pelvis demonstrates bowel distribution suggestive of malrotation, with the majority of small bowel in the right hemiabdomen and large bowel in the left hemiabdomen; the cecum is located in the pelvis, and oral contrast is present.
B. Initial axial CT image (preoperative diagnosis): corroborates the right-sided predominance of small bowel and left-sided large bowel. No CT evidence of bowel obstruction or inflammatory changes is seen.

Figure 2: A. Post-Ladd procedure coronal CT, on admission: Coronal CT abdomen/pelvis demonstrates a markedly fluid-filled, distended stomach. Bowel distribution is consistent with expected post-Ladd positioning, with small bowel in the right hemiabdomen and large bowel in the left hemiabdomen. The cecum remains in the pelvis, and oral contrast is present.
B. Post-Ladd procedure axial CT, on admission: Axial CT image corroborates gastric distension and expected post-Ladd bowel distribution. No CT evidence of bowel obstruction or inflammatory changes is seen. A small amount of fecal material is present within the colon.

epigastric abdominal pain beginning on postoperative day (POD) five (POD5) following an elective robotic-assisted laparoscopic Ladd procedure. His symptoms intensified despite conservative outpatient management, prompting an emergency room visit on POD9.

The patient reported a lifelong history of intermittent GI complaints beginning in childhood, including chronic diarrhea, postprandial bloating, early satiety, and vague abdominal discomfort. These symptoms had previously been attributed to irritable bowel syndrome. He described eating small and frequent meals throughout his life. Six months prior, CT of the abdomen and pelvis revealed intestinal malrotation **(Figure 1)**. Additional evaluation for chronic GI conditions, including celiac serologies, fecal calprotectin, and pancreatic elastase testing, was unremarkable. No preoperative upper GI contrast study or esophagogastroduodenoscopy was performed to directly assess duodenal patency.

Given the correlation between his lifelong symptoms and CT findings of malrotation, and after exclusion of alternative etiologies, elective surgical correction was pursued. Alternative diagnoses, including functional dyspepsia and gastroparesis, were considered but felt to be less consistent with the imaging findings. After an informed discussion, the patient underwent an elective robotic-assisted laparoscopic Ladd procedure. Intraoperative findings confirmed intestinal malrotation. Ladd bands were identified and divided, and the mesenteric base was widened. An appendectomy was performed. The duodenum was noted to have an abnormal retroperitoneal orientation, but no discrete stenosis or luminal narrowing was appreciated at the time of the index procedure. No intraoperative assessment of duodenal patency (e.g., passage of a nasogastric tube through the duodenum or endoscopic evaluation) was performed. The initial postoperative course was uneventful, with the return of

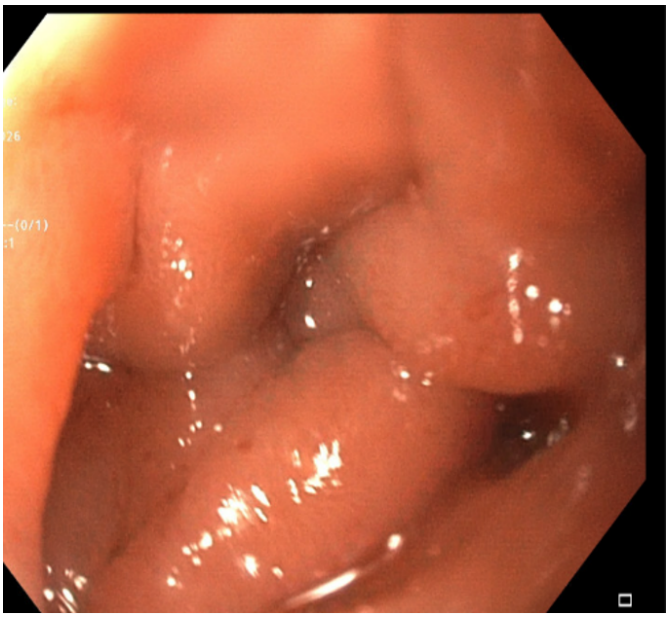

Figure 3: Esophagogastroduodenoscopy (EGD) demonstrates high-grade narrowing of the second portion of the duodenum (D2). The lumen could not be traversed with the gastroscope. The mucosa appeared grossly normal, suggesting extrinsic compression.

Figure 4: Upper GI contrast study performed on postoperative day 2 following gastrojejunostomy demonstrates free passage of contrast through the anastomosis without evidence of leak or obstruction. Opacified small-bowel loops appear unremarkable.

bowel function and advancement of diet by POD2; the patient was discharged on POD3.

On readmission at POD9, the patient was hemodynamically stable. Examination revealed a soft, mildly distended abdomen with epigastric tenderness but no peritoneal signs. Laboratory studies, including serum lactate, were within normal limits. CT demonstrated marked gastric distension with expected post-Ladd bowel positioning and no evidence of obstruction, perforation, or abscess **(Figure 2)**. The patient was made NPO and underwent nasogastric decompression. Nasogastric output exceeded two liters daily over 72 hours, with persistent symptoms on clamp trials. Upper GI fluoroscopy on HD3 showed contrast passing through the duodenum without a clear transition point.

Given radiographic – clinical discordance, EGD was performed on HD5 **(Figure 3)**, revealing a normal esophagus, stomach, and duodenal bulb but severe narrowing of the second portion of the duodenum (D2), which was impassable with the gastroscope. The mucosa was grossly normal. These findings were consistent with a high-grade extrinsic duodenal obstruction. The differential diagnosis included postoperative edema, hematoma, kinking, internal hernia, dysmotility, and a pre-existing congenital lesion unmasked by surgery. The extrinsic compression pattern with normal mucosa

Table 1: Timeline of Events after Initial Ladd Procedure

Time after (days)			Event with Description
Ladd Procedure	**ED Presentation**	**Gastrojejunostomy**	
0			Elective robotic-assisted laparoscopic Ladd procedure
5			Onset of progressive nausea, vomiting, and epigastric pain
9	1		Presented to ED; CT shows a dilated stomach without clear SBO.
10	2		Admission: NPO with persistent high-volume bilious NG output (2.0L/day)
11	3		Upper GI fluoroscopy: expected post-Ladd bowel positioning; contrast passes through the duodenum
12	4		Did not tolerate NG tube clamps. Required antiemetic treatment
13	5		EGD: narrowing of D2, gastroscope impassable, suggesting duodenal obstruction.
14	6		Diagnostic laparoscopy, intraoperative EGD, and open laparotomy.
15	7	1	Gastrojejunostomy with leak test.
16-18	8-10	2-4	Dumping syndrome (postprandial diarrhea, nausea, diaphoresis); approximately 8% body weight loss; PPI initiated for reflux.
16	8	2	Upper GI contrast study demonstrated no leak or obstruction.
17	9	3	Dietary management education of dumping syndrome.
20	12	6	Discharged with stable vitals, tolerating oral diet without nutritional supplementation.
34	26	20	Obstructive symptoms resolved; weight stabilized; dumping episodes decreasing on modified diet; PPI continued.

ED, emergency department; CT, computed tomography; SBO, small bowel obstruction; NPO, nil per os; NG, nasogastric; GI, gastrointestinal; EGD, esophagogastroduodenoscopy; PPI, proton pump inhibitor.

on EGD and absence of inflammatory changes on CT argued against an intrinsic process. However, a pre-existing congenital component could not be excluded without baseline duodenal assessment.

On HD6 (POD14), diagnostic laparoscopy revealed dense adhesions tethering the duodenum to the retroperitoneum. Partial lysis and intraoperative EGD were performed, but obstruction persisted. Given limited visualization and concern for vascular proximity, conversion to an open laparotomy was undertaken. Further exploration revealed dense tissue that fixed the stenotic segment of the duodenum to the retroperitoneum, near major vascular structures, including the inferior vena cava. Without histologic sampling, the nature of this tissue could not be determined. Complete duodenal mobilization was deemed unsafe given vascular proximity, and gastrojejunostomy was performed to bypass the obstruction. A stapled side-to-side gastrojejunostomy was created and reinforced with sutures. Intraoperative leak testing with endoscopic insufflation confirmed a patent anastomosis without leak.

Postoperatively, the patient developed early dumping syndrome characterized by postprandial diarrhea, nausea, and diaphoresis, with approximately 8% body weight loss (from 82 kg to 75.4 kg). Symptoms were managed with dietary modification consisting of small, frequent, high-protein, low-simple-carbohydrate meals. No parenteral or enteral nutritional support was required. A proton pump inhibitor was initiated for reflux symptoms. On POD2, an upper GI contrast study confirmed anastomotic patency without leak **(Figure 4)**. He was discharged on POD6, tolerating oral intake without supplemental nutrition. At two-week follow-up, obstructive symptoms had resolved, weight had stabilized at 76 kg, dumping episodes were decreasing in frequency on the modified diet, and the proton pump inhibitor was continued. No additional imaging or endoscopic evaluation was performed at that visit. **(Table 1)** describes the timeline of events.

3. Discussion

Our patient's chronic nonspecific GI symptoms (diarrhea, postprandial bloating, early satiety, and abdominal discomfort) were consistent with the adult malrotation profile described by Nehra and Goldstein, who reported abdominal pain in 87%, nausea in 31%, and vomiting in 37% of their cohort [8].

When complicated by midgut volvulus, malrotation is a surgical emergency. In both pediatric and adult populations, the standard operative treatment for symptomatic malrotation is the Ladd procedure [1, 6]. The complications of the Ladd procedure include intestinal obstruction and, less commonly, recurrent midgut volvulus [7]. It should be noted that this complication data derives predominantly from pediatric series [7, 10]. In adults, malrotation is frequently detected incidentally on cross-sectional imaging performed for unrelated indications, and the clinical presentation differs from the pediatric setting [3]. Direct extrapolation from pediatric post-Ladd complication data to adult patients must therefore be made cautiously, given differences in tissue biology, degree of retroperitoneal fixation, and adhesion formation characteristics [11]. While duodenal obstruction has been documented as a symptom of Ladd bands themselves, very few case studies describe duodenal obstruction after the Ladd procedure [9]. Mizuta et al (2022) described a case of a descending duodenal obstruction and subsequent duodenal dysmotility disorder, but this was found to be secondary to compression by a pancreatic fistula [12]. A case of intrinsic duodenal stenosis post-Ladd was

described by Akomea-Agyin et al. (2024); however, the patency of the duodenum was not tested during the initial Ladd procedure, suggesting that the stenosis could have been present pre-Ladd procedure [13]. Both of these reports involved clinical contexts that may not be directly comparable to the present case, underscoring the paucity of adult-specific data on post-Ladd duodenal obstruction. To our knowledge, early D2 obstruction recognized after an adult Ladd procedure, in the absence of a documented extrinsic compressive lesion such as a pancreatic fistula, has rarely been described in the literature.

The imaging and endoscopic findings argued against an intrinsic mucosal process, and the intraoperative finding of dense tissue tethering the duodenum to the retroperitoneum was most consistent with either congenital fixation or early postoperative adhesive change. At only 14 days postoperatively, mature fibrosis would not be expected based on the known timeline of adhesion formation [11]. The term "dense tissue" is therefore used descriptively without implying chronic fibrosis.

In pediatric populations, upper GI contrast studies and abdominal ultrasound are established diagnostic modalities for malrotation and associated duodenal obstruction [10, 14]. In adults, CT is more frequently the initial diagnostic study, supplemented by upper GI contrast series and sonographic assessment of SMA – SMV orientation [3]. In the postoperative setting, however, these modalities may be insufficient. In our case, neither CT nor a fluoroscopic contrast study identified the D2 obstruction; passage of contrast through the duodenum did not equate to functional patency. EGD provided the critical diagnostic information by directly visualizing the degree of luminal narrowing and should be considered when obstructive symptoms persist despite non-diagnostic imaging.

Typically, bypassing duodenal stenosis is performed with a duodenoduodenostomy, which requires mobilization of the duodenum [13, 14]. Due to the close anatomical association of the duodenal segment with retroperitoneal vessels and the significant risk of vascular injury in our patient, performing a duodenoduodenostomy was deemed unsafe. Instead, a gastrojejunostomy was performed. Although the patient's postoperative course was complicated by dumping syndrome, his symptoms improved substantially with dietary modification and continued to decrease in frequency through the two-week follow-up period. Whether this approach is generalizable to other patients with post-Ladd duodenal obstruction cannot be determined from a single case.

This case has several important limitations. First, neither preoperative imaging nor intraoperative assessment directly evaluated duodenal patency before or during the index Ladd procedure; without a baseline study, it cannot be determined whether the D2 narrowing was a new postoperative finding or a pre-existing congenital abnormality unmasked by surgery. Second, follow-up was limited to two weeks after gastrojejunostomy; longer-term data on weight recovery, nutritional sufficiency, bile reflux, and anastomotic patency are needed to fully assess the outcome of bypass. Third, histologic characterization of the tissue fixing the duodenum was not obtained, precluding definitive conclusions about the mechanism of obstruction. As with any single case, these findings are hypothesis-generating, and the applicability of predominantly pediatric post-Ladd complication data to adults remains uncertain.

4. Conclusion

Symptomatic intestinal malrotation in adults may present with chronic nonspecific GI symptoms, and the postoperative course after the Ladd procedure may be complicated by previously unrecognized proximal duodenal pathology. D2 obstruction should be considered when persistent high-output gastric decompression follows an adult Ladd procedure, particularly when standard imaging fails to identify a transition point. Endoscopic evaluation can provide critical diagnostic information when clinical and radiographic findings are discordant. Operative strategy should be individualized based on intraoperative anatomy and safety considerations. Preoperative assessment of duodenal patency may help distinguish congenital from acquired obstruction in this setting.

Conflicts of Interest

The authors declare that they have no financial or non-financial conflicts of interest related to this work. The authors report no relevant commercial relationships, consultancies, advisory roles, honoraria, stock ownership, patents, paid expert testimony, or institutional relationships that could have influenced the design, interpretation, writing, or publication of this case report.

Funding Source

This research received no specific grant from any funding agency in the public, commercial, or not-for-profit sectors.

Acknowledgments

None.

Informed Consent

Written informed consent was obtained from the patient for publication of this case report and accompanying images. This case report was prepared in accordance with the CARE guidelines [15].

Large Language Model

The authors declare that generative artificial intelligence tools (Claude, Anthropic) were used to assist with language refinement and grammar checking during the preparation of this manuscript. The authors reviewed and verified all content, and they take full responsibility for the integrity and accuracy of the work.

Author Contributions

AA contributed to conceptualization, investigation, data curation, writing the original draft, writing review and editing, and project administration. AK contributed to the investigation, data curation, writing the original draft, and writing review and editing. BS contributed to writing the review, editing, and supervision. AG contributed to writing, reviewing, editing, and supervision. YH contributed to conceptualization, writing review and editing, and supervision.

Data Availability

All data supporting the findings of this case report are included within the published article, figures, and table. No additional public dataset was generated or analyzed for this study. Additional patient-level clinical information and source imaging are not publicly available to protect patient privacy and confidentiality and because they are subject to institutional and consent-related restrictions. Limited de-identified information may be made available by the corresponding author upon reasonable request, subject to institutional policies and applicable privacy regulations.

References

1. Alani M, Rentea RM. Midgut Malrotation [Internet]; 2026. StatPearls Publishing, Treasure Island (FL). Available from: https://www.ncbi.nlm.nih.gov/books/NBK560888.
2. Fu T, Tong WD, He YJ, Wen YY, Luo DL, Liu BH. Surgical management of intestinal malrotation in adults. World J Surg. 2007;31(9):1797-803. [PMID: 17457643, https://doi.org/10.1007/s00268-007-9018-2].
3. Pickhardt PJ, Bhalla S. Intestinal malrotation in adolescents and adults: spectrum of clinical and imaging features. AJR Am J Roentgenol. 2002;179(6):1429-35. [PMID: 12438031, https://doi.org/10.2214/ajr.179.6.1791429].
4. Aboagye J, Goldstein SD, Salazar JH, Papandria D, Okoye MT, Al-Omar K, et al. Age at presentation of common pediatric surgical conditions: Reexamining dogma. J Pediatr Surg. 2014;49(6):995-9. [PMID: 24888850, https://doi.org/10.1016/j.jpedsurg.2014.01.039].
5. Butterworth WA, Butterworth JW. An adult presentation of midgut volvulus secondary to intestinal malrotation: A case report and literature review. Int J Surg Case Rep. 2018;50:46-9. [PMID: 30077833, PMCID: PMC6083817, https://doi.org/10.1016/j.ijscr.2018.07.007].
6. Matzke GM, Dozois EJ, Larson DW, Moir CR. Surgical management of intestinal malrotation in adults: comparative results for open and laparoscopic Ladd procedures. Surg Endosc. 2005;19(10):1416-9. [PMID: 16151680, https://doi.org/10.1007/s00464-004-8249-7].
7. Mitsunaga T, Saito T, Terui K, Nakata M, Ohno S, Mise N, et al. Risk Factors for Intestinal Obstruction After Ladd Procedure. Pediatr Rep. 2015;7(2):5795. [PMID: 26266030, PMCID: PMC4508621, https://doi.org/10.4081/pr.2015.5795].
8. Nehra D, Goldstein AM. Intestinal malrotation: varied clinical presentation from infancy through adulthood. Surgery. 2011;149(3):386-93. [PMID: 20719352, https://doi.org/10.1016/j.surg.2010.07.004].
9. Lieu DQ, Dung TN, Long TB, Anh TN, Dung LQ, Duc NM. A rare case of Ladd's band causing duodenal occlusion in an adult with intestinal malrotation. Radiol Case Rep. 2023;18(10):3735-8. [PMID: 37636537, PMCID: PMC10447930, https://doi.org/10.1016/j.radcr.2023.08.001].
10. Applegate KE, Anderson JM, Klatte EC. Intestinal malrotation in children: a problem-solving approach to the upper gastrointestinal series. Radiographics. 2006;26(5):1485-500. [PMID: 16973777, https://doi.org/10.1148/rg.265055167].
11. Fatehi Hassanabad A, Zarzycki AN, Jeon K, Deniset JF, Fedak PWM. Post-Operative Adhesions: A Comprehensive Review of Mechanisms. Biomedicines. 2021;9(8). [PMID: 34440071, PMCID: PMC8389678, https://doi.org/10.3390/biomedicines9080867].
12. Mizuta N, Kikuchi T, Fukuda Y. Adult Intestinal Malrotation Treated with Laparoscopic Ladd Procedure. Case Rep Surg. 2022;2022:6874885. [PMID: 36304201, PMCID: PMC9596249, https://doi.org/10.1155/2022/6874885].
13. Akomea-Agyin E, Agbedinu K, Dally CK, Galley F, Kankam EO, Banini GE. Duodenal stenosis in adult malrotation: When Ladd procedure is not enough: A case report. Int J Surg Case Rep. 2024;119:109713. [PMID: 38703614, PMCID: PMC11087998, https://doi.org/10.1016/j.ijscr.2024.109713].
14. Mustaqim K, Mohd Shah MS, Muhammad Asri NA. Double Whammy: Duodenal Stenosis and Gastrointestinal Malrotation. Cureus. 2023;15(3):e36137. [PMID: 37065346, PMCID: PMC10101184, https://doi.org/10.7759/cureus.36137].
15. Riley DS, Barber MS, Kienle GS, Aronson JK, von Schoen-Angerer T, Tugwell P, et al. CARE guidelines for case reports: explanation and elaboration document. J Clin Epidemiol. 2017;89:218-35. [PMID: 28529185, https://doi.org/10.1016/j.jclinepi.2017.04.026].