ASIDE Health Sciences

Review Article

Ocular Trauma Patterns in the Middle East and North Africa: A Scoping Review with Emphasis on Iraq

Elaf Falih Abbas[1], Mohammed Mousa Imran[1], Mustafa Yahya Saleh[1], Huda Omran[2,*]

1-Ophthalmology Department, AlSader Teaching Hospital, Basra, Iraq
2-Genetic Department, Aldafter Medical Center, Arabian Gulf University, Manama, Bahrain

ARTICLE INFO

Article history:
Received 15 Mar. 2026
Received in revised form 18 Apr. 2026
Accepted 26 Apr. 2026
Published 28 Apr. 2026

Keywords:
Ocular Trauma
War Injuries
Blindness
MENA
Iraq
Scoping Review

ABSTRACT

Background: Ocular injury is one of the leading causes of preventable monocular blindness globally. These injuries have multiple etiologies, with socioeconomic factors and geopolitical instability as the main drivers. A unique combination of these factors can be seen in the MENA region.
Methods: This scoping review used a structured analysis of published research. We searched PubMed and Scopus (2004–2025) using terms for ocular trauma and MENA countries. Two reviewers independently screened titles, abstracts, and full texts against predefined inclusion criteria that accepted original research, reviews, and case series; a third reviewer resolved disagreements. Data were extracted using a standardized form and synthesized descriptively. No formal quality appraisal was performed.
Results: The search identified 918 records, of which 25 were included. Etiological patterns differed markedly across countries. In Iraq, conflict-related mechanisms (blasts, bullets) dominated in military cohorts, alongside civilian motorcycle accidents. In other MENA countries, road traffic accidents and occupational injuries were more frequently reported. Management challenges in Iraq were compounded by limited primary eye care infrastructure and high rates of enucleation. Pediatric trauma was also a major concern. Population-based civilian data from conflict-affected settings remain scarce.
Conclusion: Ocular trauma is a major health issue in Iraq, with patterns suggesting an association with decades of conflict. However, population-based comparative data are very limited. This scoping review highlights evidence gaps, particularly the scarcity of population-based civilian data from conflict-affected settings.

1. Introduction

Ocular trauma is a critical public health problem, accounting for a substantial proportion of monocular blindness worldwide. It significantly affects individual quality of life, reducing their economic productivity and increasing healthcare costs.

The pattern of injury is largely linked to the local environment, culture, industry, and safety standards. The MENA region, with its vast geographic and political diversity, offers a critical lens for examining these relationships. While countries in the Gulf Cooperation Council (GCC) have advanced rapidly in healthcare, including ophthalmic care, others deal with the aftermath of conflict, economic instability, and limited healthcare resources. Iraq stands out within this continuum, having endured decades of war, economic sanctions, and internal conflict. The ophthalmological consequences of this are severe and distinct.

This review aims to evaluate the available scientific literature on ocular trauma in the MENA region by comparing the etiological factors and management challenges in Iraq with those of neighboring countries. Based on the available evidence, we interpret that prolonged conflict in Iraq is associated with a distinct profile of severe ocular injuries and treatment needs, though population-based comparative data remain limited.

2. Methods

2.1. Study Design and Selection

This review was conducted as a scoping review following the framework of Arksey and O'Malley and reported in accordance with the PRISMA ScR (Preferred Reporting Items for Systematic Reviews and Meta Analyses extension for Scoping Reviews) checklist. A protocol was not registered. We searched PubMed and Scopus for articles published between January 2004 and June 2025. An initial PubMed search identified relevant keywords. These were used in a systematic search strategy that combined free-text and Boolean terms applied to both databases. These search terms for ocular trauma and MENA countries included the following:

- Ocular trauma terms: ("ocular trauma" OR "eye injury" OR "ocular injury" OR "open globe" OR "penetrating eye injury")
- Geographic terms: ("Middle East" OR "North Africa" OR MENA OR Iraq OR Iran OR "Saudi Arabia" OR Jordan OR Palestine OR Gaza OR "United Arab Emirates" OR Qatar OR Kuwait OR Oman OR Bahrain OR "Syrian Arab Republic" OR Lebanon OR Egypt OR Libya OR Tunisia OR Algeria OR Morocco OR Yemen)

* Corresponding author: Huda Omran, Genetic Department, Aldafter Medical Center, Arabian Gulf University, Manama, Bahrain. Email: hudamossa.omran@gmail.com

Published and owned by PubPorta Publishing LLC. Academic oversight and scholarly guidance are provided by the American Society for Inclusion, Diversity, and Equity in Healthcare (ASIDE). ISSN (Print) 3067-8730, ISSN (Online) 3067-8749. ©2026 The Author(s). This is an open-access article distributed under the terms of the Creative Commons Attribution 4.0 International License (CC BY 4.0). Hosting by ASIDE Journals.

Citation: Abbas EF, Imran MM, Saleh MY, Omran H. Ocular Trauma Patterns in the Middle East and North Africa: A Scoping Review with Emphasis on Iraq. ASIDE Health Sci. 2026;2(2):40-46, doi:10.71079/ASIDE.HS.042826665

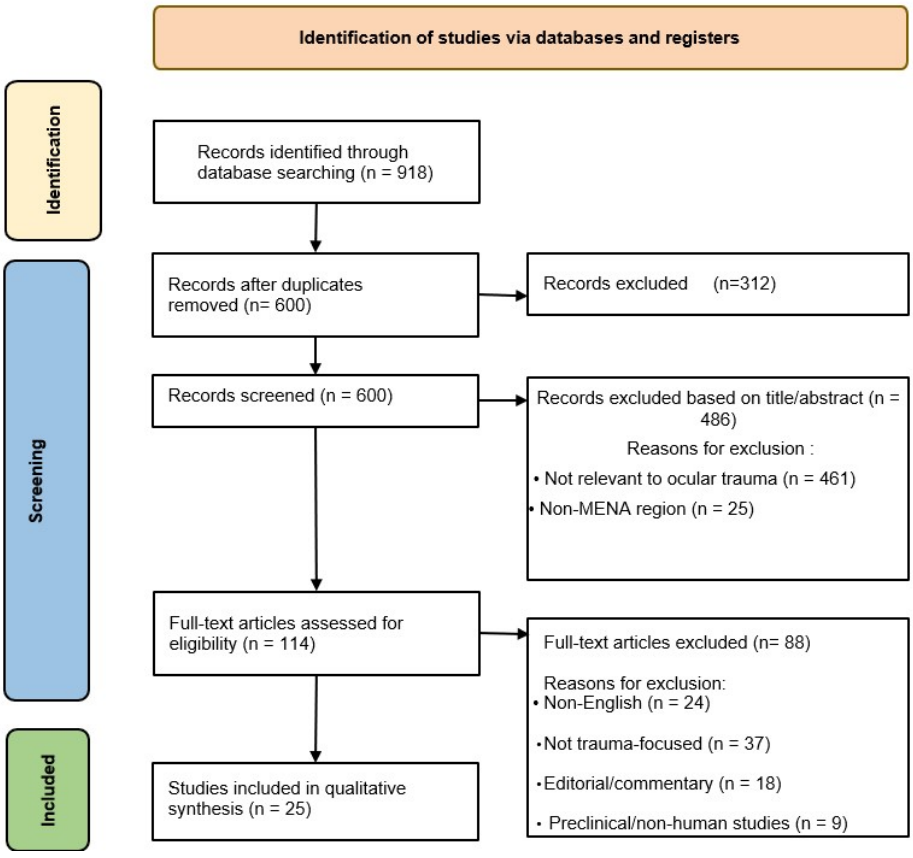

Figure 1: PRISMA flow diagram for the identification and selection of studies eligible for this review.

- Supplementary terms: "war injury," "blast injury," "occupational injury," "road traffic accident."

Two reviewers independently screened titles and abstracts, followed by full-text review. A third reviewer resolved disagreements. The inclusion criteria were original research, reviews, and case series in English reporting on the etiology, epidemiology, or management of ocular trauma in MENA countries. Exclusion criteria: non-English publications, studies not focused on trauma, editorials, preclinical studies, and studies conducted outside the MENA region.

Articles were systematically grouped by their primary country or region of focus, primary mechanism of injury (e.g., blast, road traffic accidents RTA, occupational), and key clinical themes (e.g., pediatric trauma, surgical outcomes, rehabilitation). Data relevant to Iraq were extracted and analyzed in parallel with data from other MENA nations, like Iran, Saudi Arabia, and Jordan, to enable a direct comparative analysis of epidemiological patterns, management protocols, and public health implications.

2.2. Data Extraction and Synthesis

Microsoft Excel was used to manage extracted data. Authors, year, country, study design, population (civilian, military, or mixed), primary injury mechanism, and key clinical findings were collected. Data were grouped by country **(Figure 1)**. Given heterogeneity in study designs and population, no meta-analysis was performed. Synthesis is descriptive and comparative. All included studies were summarized in a single table **(Table 1)**. Risk of bias assessment was not performed, consistent with scoping review methodology. Findings were presented as descriptive patterns rather than definitive comparative epidemiology.

3. Results

The initial search yielded 918 records. After duplications had been removed, 600 titles and abstracts were screened, and 486 were excluded. The full text of 114 articles was assessed for eligibility. A total of 25 studies from the MENA region met the inclusion criteria and were included in the qualitative synthesis **(Figure 1)**. Of the 25 included studies, 11 focused on Iraq (including those that covered both Iraq and Afghanistan), 3 on Iran, 1 on Saudi Arabia, 1 on Jordan, 2 on Palestine/Gaza, 1 on the Levant, 1 on Turkey, and 1 examined the MENA region as a whole. Several studies involved military personnel, while others focused on civilian or pediatric populations. To ensure transparency, the evidence is presented in two tiers: primary epidemiologic studies (cross sectional, cohort, and case series reporting original trauma data) form the basis for all comparative statements about injury mechanisms, severity, and outcomes. Reviews, meta-analyses, and service-oriented papers are cited only for contextual background (e.g., infrastructure or rehabilitation discussions) and are not used for direct epidemiological comparisons.

Epidemiological patterns and etiological comparison The etiology of ocular trauma in MENA is a direct reflection of local realities. The provided literature reveals a clear contrast between conflict-affected zones like Iraq and more stable regions. As shown in Table 1.

While Iraq represents an extreme within the conflict injury spectrum, a gradient of instability and resource scarcity exists across the region.

Table 1: Comparison of Ocular Trauma Epidemiology Across Countries/Regions in the MENA Region (n = 25) Tier 1 (primary epidemiologic) studies are marked with †.

Author(s), Year	Country/ Region	Study Design	Sample Size (N)	Study Setting	Denominator / Population at Risk	Population	Primary Mechanism(s)	Key Findings
Sulaiman II et al., 2024	Iraq	Review/meta analysis (Tier 2)	688	Military & civilian hospitals	Not applicable	Civilian/ military	Ballistic	High enucleation rates; penetrating orbital trauma
Blanch RJ et al., 2011†	Iraq	Case series	63	British military hospital (Iraq/Afghanistan)	All combat eye injuries referred	Military personnel	Blast/ fragmentation	52% open globe
Justin GA et al., 2020†	Iraq	Cohort	652	U.S. military tertiary hospital	All orbital fractures referred	Military personnel	Blast	31.3% NLP
Thach AB et al., 2008†	Iraq	Case series	797 severe eye injuries	U.S. military registry	Combat zone injuries 2003–2005	Military personnel	Blast/ fragmentation	116 enucleations; 438 open globe
Hashim ZA et al., 2024†	Iraq	Cross sectional	335	Iraqi tertiary hospitals	Consecutive motorcycle accident patients	Civilian	Motorcycle accidents	17% severe; lid/corneoscleral injuries
Yulish M et al., 2012†	Levant	Case series	119	Regional hospital	Agricultural workers presenting with eye injury	Agricultural workers	Olive harvesting	Corneal perforations
Hashemi H et al., 2015†	Iran	Cross sectional	5190	Population based	General population aged 40–64	Civilian	Mixed	Lifetime trauma prevalence 8.57% (blunt 3.91%, sharp 3.82%, chemical 1.93%)
Challa NK et al., 2024†	Saudi Arabia	Cross sectional	300 truck drivers	Truck driving company	All active drivers	Civilian	RTA	Refractive error linked to RTA risk
Odat TAM et al., 2014†	Jordan	Case series	21	Tertiary eye center	Consecutive cases	Civilian	Prickly pear spine	Keratoconjunctivitis
Al Barqi M et al., 2022†	Saudi Arabia	Case series	3	Tertiary eye center	Fireworks injuries during celebrations	Civilian	Fireworks	Severe open globe
Al Amry M et al., 2021†	Saudi Arabia	Case series	36	Tertiary eye center, Riyadh	Consecutive terror-related trauma	Civilian	Terror-related (blast)	77.8% NLP; devastating outcomes
Harris JP et al., 2021†	Iraq	Cohort	890 eyes	U.S. military registry	All combat open globe injuries	Military personnel	Blast	32.02% open globe injuries
Shakarchi F., 2025	Iraq	Cross-sectional (service)	2805 primary health centers	National primary care survey	All PHCs in Iraq	Civilian	Mixed (context)	Only 2%(n=63) offer eye services
Bahremani E et al., 2023	MENA region	Cross-sectional (burden study)	Not specified	Global Burden of Disease	MENA population	Civilian	Mixed (all cause)	Iraq age-standardized prevalence 7188.6/100,000
Holmes CJ et al., 2019†	Iraq	Cohort	19	British military registry	All combat eye injuries requiring surgery	Military personnel	Blast/ fragmentation	Outcomes of evisceration/ enucleation
Keenan TDL et al., 2011†	Palestinian territories	Case series	32	Tertiary hospital, Gaza	Consecutive enucleations/ eviscerations	Civilian/ mixed	Conflict related	High rates of enucleation
Ciftci MD et al., 2023	Turkey	Case series (surgical technique)	9	Tertiary eye center	Corneal perforations	Civilian	Corneal perforations	Sandwich technique + amniotic membrane is effective
Arevalo JF et al., 2012	Saudi Arabia	Review (Tier 2)	Not applicable	Not applicable	Not applicable	Civilian	Penetrating trauma	Sympathetic ophthalmia prevention
Hayder Abdul Al Husain et al., 2023†	Iraq	Cross sectional	120 pediatric patients	Pediatric ophthalmology clinic	Consecutive clinic attendees	Pediatric	Mixed	Home-occurring open globe wounds are preventable
Hosseini H et al., 2011†	Iran	Cross sectional	278	Tertiary hospital (southern Iran)	All pediatric ocular trauma	Pediatric	Sharp/blunt	Boys predominantly affected

MENA, Middle East and North Africa; NLP, No Light Perception; PHC, Primary Health Center; RTA, Road Traffic Accident. † Denotes studies included in the primary ocular trauma analysis.

Table 1: Comparison of Ocular Trauma Epidemiology Across Countries/Regions in the MENA Region (n = 25) Tier 1 (primary epidemiologic) studies are marked with †.

Author(s), Year	Country/ Region	Study Design	Sample Size (N)	Study Setting	Denominator / Population at Risk	Population	Primary Mechanism(s)	Key Findings
Al Dahan D et al., 2019†	Saudi Arabia	Cross sectional	199 pediatric prosthesis patients	Tertiary referral center	All pediatric prosthesis fittings	Pediatric	Mixed	Prosthesis indications after trauma
Masrur A et al., 2025†	Gaza (Palestine)	Observation cohort	23	4 hospitals in Gaza	Consecutive CNN registry cases (March–Sept 2024)	Pediatric (<20 years)	Explosive / penetrating (conflict-related)	11/23 (48%) ocular trauma; severe visual loss including NLP; communication barriers main challenge
Mousavi B et al., 2009	Iran	Cross-sectional (chemical warfare)	147	Chemical warfare survivor's registry	Iranian chemical warfare survivors	Civilian	Chemical weapons	Reduced quality of life
Geiling J et al., 2012	Iraq	Review (Tier 2)	Not applicable	Not applicable	Not applicable	Military veterans	Conflict-related	Long-term care costs
Ramadhan HA et al., 2025†	Iraq	Cross-sectional	71	Halabja population survey	Chemically-exposed population	Civilian	Chemical weapons	Corneal injuries

MENA, Middle East and North Africa; NLP, No Light Perception; PHC, Primary Health Center; RTA, Road Traffic Accident. † Denotes studies included in the primary ocular trauma analysis.

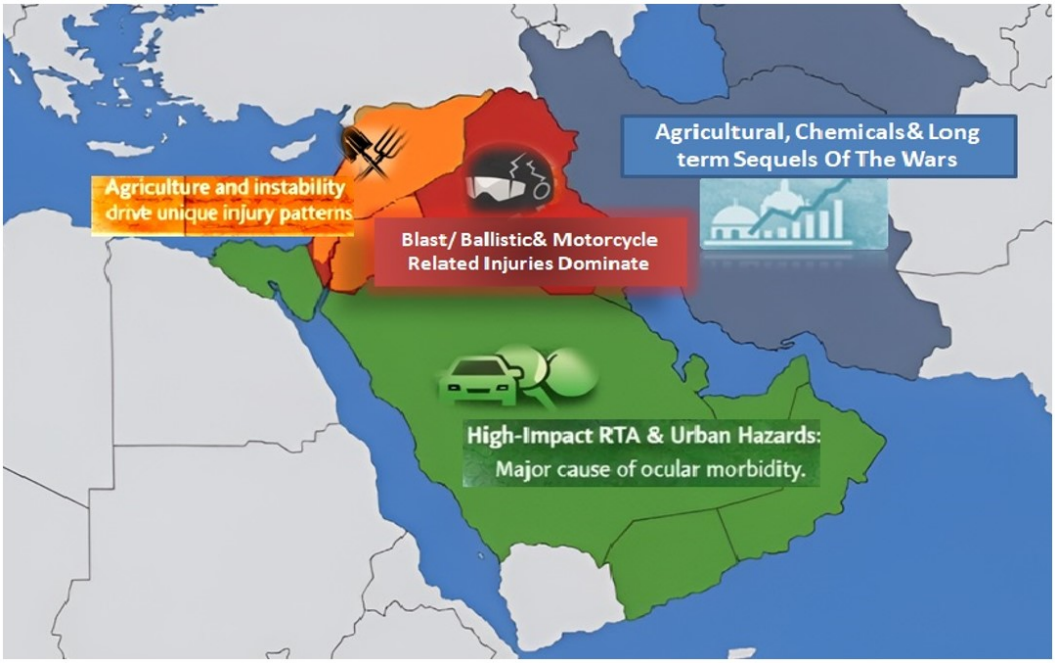

Figure 2: Schematic illustration of key etiological factors and patterns of ocular trauma.

The data from Iraq is affected by the consequences of modern conflicts. Studies on military personnel from Operation Iraqi Freedom detail high rates of open globe wounds from blast and fragmentation injuries [1, 2]. A study by Justin and his coworkers of U.S. personnel evacuated to a tertiary military hospital from Iraq (2001 – 2011) found that orbital fractures occurred in 34.2% (304/890) of eye injuries, with 31.3% (95/304) of those cases resulting in no light perception [3]. Earlier data from the 2003 – 2005 periods documented 797 severe eye injuries, which included 438 open globe injuries (49 bilateral) and 116 eyes requiring removal (enucleation/evisceration) [4]. Concurrently, civilian studies point to motorcycle accidents as a major cause [5] of ocular morbidity, suggesting a dual burden of conflict-related and conventional trauma. Hashim and his collaborators documented that Iraqi tertiary hospitals reported 335 ophthalmological accidents from motorcycle crashes, predominantly affecting young males (mean age 27.8 years) [5]. Injuries were classified as mild in 55.82%, moderate in 27.16%, and severe in 17.01% of cases, with lid lacerations (60.9%) and corneoscleral injuries (22.1%) being most common [5].

In contrast, studies from other regions highlight different priorities. Occupational hazards are prominent, including industrial accidents and olive-harvesting injuries in the Levant [6]. RTA is a universal cause, detailed in studies from Iran [7] and Saudi Arabia [8]. Unique environmental injuries include prickly pear spine keratoconjunctivitis in Jordan [9] and fireworks injuries during celebrations in Saudi Arabia [10]. Terror related ocular trauma is reported from a tertiary center in Saudi Arabia [11], indicating the high rate of ocular trauma in conflict affected settings; similar patterns are observed in Gaza [12, 13]. Challa and Al Rasheed linked refractive error and abnormal stereopsis among truck drivers in Saudi Arabia to the risk of road traffic accidents, adding depth to the understanding of RTA etiologies [8]. This variation in the etiology of ocular trauma, from high-velocity conflict-related injuries to occupational and environmental mechanisms, directly influences the spectrum of injury severity, clinical presentation, and subsequent management challenges encountered across the region. These relationships between cause and clinical consequence are explored in the following section. The variation in the etiology of ocular trauma is illustrated in **(Figure 2)**.

3.1. Disparities in Clinical Management and Visual Prognosis

The nature of trauma determines its severity. Iraqi data emphasize high energy, devastating injuries often presenting with extensive tissue loss, multiple intraocular foreign bodies, and associated maxillofacial trauma [2, 14]. In Iraq, the capacity to manage this trauma burden is severely constrained. A study revealed that only 2% of Iraq's primary health centers offer eye-related services, which contributes to tertiary hospitals being overwhelmed; more than half of specialist hospital consultations are for conditions that are manageable at the primary level [15]. This systemic gap takes place in the context of a high overall burden of eyesight loss in Iraq (7.4% of Iraqis, all causes combined, including cataract, glaucoma, and trauma [15, 16]), which is provided here only as background on the general eye health challenge.

In other MENA settings, presentations, while serious, may more frequently involve isolated corneal abrasions, lid lacerations, or blunt trauma. **(Figure 3)** shows the different kinds of trauma reported in many studies included in this review and reflects the variation in clinical courses and, consequently, the treatment needed.

The surgical burden differs accordingly. Evisceration and enucleation rates are significantly reported in the context of military trauma from Iraq [4, 17] and in Palestinian territories [12], reflecting the severity of initial injuries and possibly delayed presentation. Surgical innovation is directed at complex reconstruction, such as managing orbital bullet injuries [2] and repairing corneal perforations using advanced techniques like the "sandwich" and amniotic membrane transplantation [18]. Managing sequelae like traumatic cataract and preventing sympathetic ophthalmia are critical concerns shared across the region [19] An important and recurrent theme is the high incidence of trauma among children, a vulnerable demographic across the MENA region. Ocular injury is a leading cause of preventable blindness in children all over the world. Studies from Iraq [20], Iran [21], and Saudi Arabia [22] consistently show that children represent a vulnerable demographic, suffering from domestic accidents and stray projectile injuries, often leading to lifelong visual disability and a need for prosthetic fitting.

The demand for pediatric prostheses following enucleation and evisceration was highlighted with this permanent need [13]. The challenges of delivering pediatric ophthalmic care in Gaza highlight how systemic collapse in conflict zones exacerbates trauma outcomes [13]. Furthermore, a study by Bahremani and colleagues confirmed that, while the prevalence of vision loss in MENA decreased by 11.1% from 1990 to 2019, the absolute number remains high at 32.5 million cases, with Iraq's age-standardized prevalence rate at 7188.6 per 100,000 [16].

Furthermore, research on Iranian chemical warfare survivors provides clear evidence of the significant reduction in quality of life associated with ophthalmologic war injuries [23], a finding with direct relevance to the Iraqi civilian population [24, 25].

3.2. Public Health Implications and Challenges

A distinguished variation exists between the advanced, well-resourced tertiary eye centers in the Gulf countries and the overwhelmed or fragmented systems in conflict zones. The Iraqi healthcare system bears a double burden: managing acute, complex war injuries requiring multi-specialty input and providing lifelong rehabilitation for survivors [2]. This includes not only prosthetic services but also low vision aid, psychological support for disfigurement and vision loss, and surgical management of late complications like glaucoma and retinal detachment. The strain on specialized ophthalmic surgical capacity is huge, Gaza, for example [12]. This disparity affects everything from timely primary repair to access to complex vitreoretinal surgery.

3.3. Etiology Specific Prevention Strategies

For Iraq, the primary preventive strategy is primarily political, focusing on conflict mitigation, mine clearance, and weapons control. Secondary prevention includes disseminating basic ocular first-aid knowledge to first responders and the public, and strengthening emergency trauma systems.

For other countries in the MENA region, effective strategies include enforcing occupational safety laws (e.g., mandatory eye protection in agriculture/industry), strict RTA prevention campaigns, public awareness on domestic hazards (fireworks, hazardous toys, chemicals), and community education on the dangers of traditional eye remedies.

3.4. Limitations and Future Directions

The nature of its source data limits this review. The dataset consists of English-language, predominantly hospital-based studies, which introduces publication bias and underrepresents cases that do not reach tertiary centers. There is an obvious scarcity of population-based incidence and prevalence studies from Iraq.

Future research efforts must prioritize several key directions to address the identified gaps. First, establishing standardized ocular trauma registries in Iraq is essential for capturing accurate national epidemiological data. Building on this foundation, conducting cost-effectiveness analyses of prevention strategies tailored to the Iraqi context, compared with other MENA countries, would help guide efficient resource allocation. Additionally, research is needed to develop and evaluate integrated care models capable of delivering proper ophthalmic trauma and rehabilitation services within resource-constrained, post-conflict primary health systems.

4. Conclusion

The etiology of ocular trauma in the MENA region is a potent indicator of its socioeconomic and political conditions. From workplace accidents to high-velocity traumas, Iraq presents itself as a significant case study in this review. The patterns observed suggest the long-term ophthalmological consequences of decades of conflict manifesting as a high volume of severe, sight-depriving injuries and a legacy of rehabilitation needs. Without population-based data, the

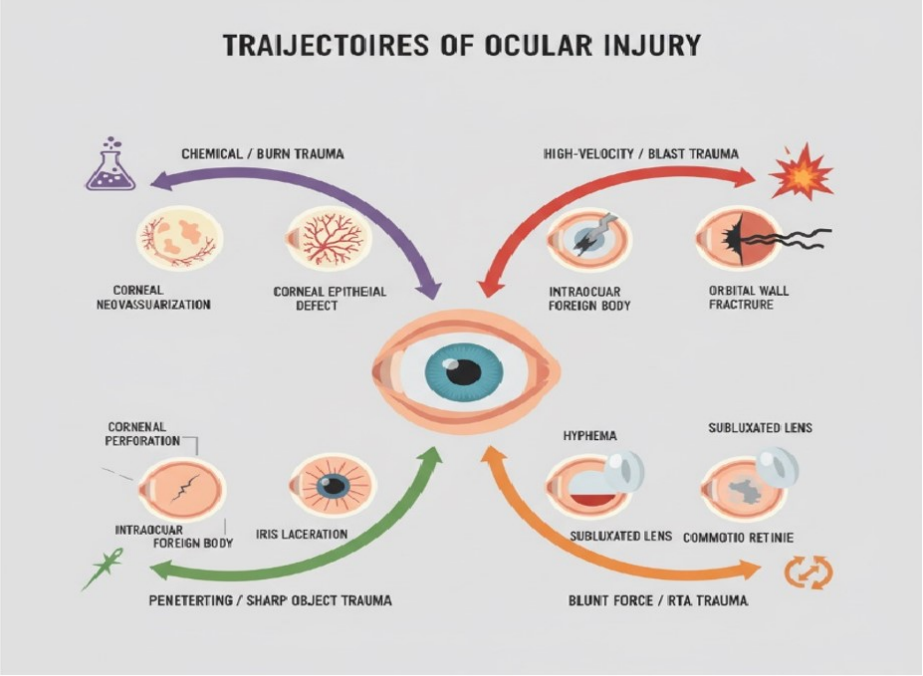

Figure 3: Schematic illustration of trajectories and clinical sequelae of ocular injury.

full clinical burden of ocular trauma in conflict-affected communities remains undetermined.

Conflicts of Interest

The authors declare that they have no known financial, personal, professional, or institutional relationships that could have influenced, or could be perceived to have influenced, the work reported in this manuscript. The authors further confirm that there are no competing interests related to the study design, literature selection, interpretation of findings, manuscript preparation, or decision to submit this article for publication.

Funding Source

The authors declare that no specific grant or funding was received for this research from any public, commercial, or not-for-profit funding agency.

Acknowledgments

None.

Institutional Review Board (IRB)

This study is a scoping review of previously published literature and did not involve direct interaction with human participants, collection of identifiable private information, intervention on patients, or use of unpublished patient-level data. Therefore, institutional review board approval was not required. Informed consent was also not applicable.

Large Language Model

During the preparation of this manuscript, the authors used ChatGPT (OpenAI) to assist in refining English-language writing and enhancing **(Figure 2)** and **(Figure 3)**. The tool was used solely for language improvement and visual clarity; AI generated no scientific content, data, or conclusions. The authors take full responsibility for the integrity and accuracy of the manuscript.

Author Contributions

EA contributed to conceptualization, methodology, validation, formal analysis, resources, writing review and editing, and supervision. MI contributed to conceptualization, methodology, validation, formal analysis, resources, writing original draft preparation, writing review and editing, and visualization. MS contributed to methodology, validation, formal analysis, resources, and writing review and editing. HO contributed to conceptualization, validation, formal analysis, resources, writing original draft preparation, writing review and editing, and visualization. All authors have read and agreed to the published version of the manuscript.

Data Availability

No new primary data were generated in this scoping review. All data synthesized in this article were derived from previously published studies identified through PubMed and Scopus searches and from the sources cited in the reference list.

References

1. Blanch RJ, Bindra MS, Jacks AS, Scott RA. Ophthalmic injuries in British Armed Forces in Iraq and Afghanistan. Eye (Lond). 2011;25(2):218-23. [PMID: 21164529, PMCID: PMC3169213, https://doi.org/10.1038/eye.2010.190].
2. Sulaiman I, Al-Wassiti ASA, Bani Saad M, Mutar MT, Abdalridha RH, Al-Badri SG, et al. Penetrating orbital trauma: Comprehensive review and meta-analysis of bullet injuries. Surg Neurol Int. 2024;15:465. [PMID: 39777188, PMCID: PMC11704445, https://doi.org/10.25259/SNI_632_2024].

3. Justin GA, Turnage WA, Brooks DI, Davies BW, Ryan DS, Eiseman AS, et al. Orbital Fractures and Associated Ocular Injuries in Operation Iraqi Freedom and Operation Enduring Freedom Referred to a Tertiary Care Military Hospital and the Effect on Final Visual Acuity. Ophthalmic Plast Reconstr Surg. 2020;36(1):55-60. [PMID: 31567916, https://doi.org/10.1097/IOP.0000000000001461].
4. Thach AB, Johnson AJ, Carroll RB, Huchun A, Ainbinder DJ, Stutzman RD, et al. Severe eye injuries in the war in Iraq, 2003-2005. Ophthalmology. 2008;115(2):377-82. [PMID: 17904224, https://doi.org/10.1016/j.ophtha.2007.04.032].
5. Hashim ZA, Mohammed SK, Abdulla MY, Fawzi HA. Presentations and Incidence of Ocular Injuries Caused by Motorcycle Accidents in Iraq. F1000Res. 2024;13:183. [PMID: 40183006, PMCID: PMC11966094, https://doi.org/10.12688/f1000research.142871.2].
6. Yulish M, Pikkel J. Olive-harvesting eye injuries. Middle East Afr J Ophthalmol. 2012;19(3):320-2. [PMID: 22837627, PMCID: PMC3401803, https://doi.org/10.4103/0974-9233.97939].
7. Hashemi H, Khabazkhoob M, Emamian MH, Shariati M, Mohazzab-Torabi S, Fotouhi A. Past History of Ocular Trauma in an Iranian Population-Based Study: Prevalence and its Associated Factors. Middle East Afr J Ophthalmol. 2015;22(3):377-82. [PMID: 26180480, PMCID: PMC4502185, https://doi.org/10.4103/0974-9233.159766].
8. Challa NK, Alrasheed SH. Refractive error and abnormal stereopsis association with road traffic accidents in Saudi Arabian truck drivers. Saudi J Ophthalmol. 2024;38(2):157-62. [PMID: 38988784, PMCID: PMC11232750, https://doi.org/10.4103/sjopt.sjopt_83_23].
9. Odat TA, Al-Tawara MJ, Hammouri EH. Prickly pear spine keratoconjunctivitis. Middle East Afr J Ophthalmol. 2014;21(1):61-5. [PMID: 24669148, PMCID: PMC3959044, https://doi.org/10.4103/0974-9233.124100].
10. Al Barqi M, Al Ghadeer H. Severe Ocular Trauma Caused by Fireworks Injury: A Case Series. Middle East Afr J Ophthalmol. 2022;29(2):103-5. [PMID: 37123429, PMCID: PMC10138128, https://doi.org/10.4103/meajo.meajo_217_22].
11. Al-Amry M, Chaudhry IA, Al-Kahatni E, Al-Ghadeer H. Terror-Related Ocular Trauma in Patients Presenting to a Tertiary Eye Center in the Middle East. Middle East Afr J Ophthalmol. 2021;28(4):226-9. [PMID: 35719291, PMCID: PMC9198528, https://doi.org/10.4103/meajo.meajo_316_21].
12. Keenan TD, Sargent NJ. Enucleation and evisceration in the palestinian territories. Middle East Afr J Ophthalmol. 2011;18(2):170-2. [PMID: 21731330, PMCID: PMC3119288, https://doi.org/10.4103/0974-9233.80708].
13. Masrur A, Yasin YAY, Alhalis EO, Abu Muaileq EAA. Challenges in providing ophthalmic care to children in Gaza. East Mediterr Health J. 2025;31(4):262-7. [PMID: 40448491, https://doi.org/10.26719/2025.31.4.262].
14. Harris JP, Justin GA, Brooks DI, Woreta FA, Agrawal RV, Ryan DS, et al. Open-globe wounds in operation Iraqi Freedom and Operation Enduring Freedom: risk factors for poor visual outcomes and enucleation. Acta Ophthalmol. 2021;99(8):904-8. [PMID: 33565256, https://doi.org/10.1111/aos.14790].
15. Shakarchi F. Eye health in post-conflict and climate-vulnerable settings: Iraq as a case study for equitable, integrated primary eye care. AJO International. 2025;2(3). [https://doi.org/10.1016/j.ajoint.2025.100148].
16. Bahremani E, Alizadeh M, Nejadghaderi SA, Noori M, Sullman MJM, Kolahi AA, et al. The burden of vision loss in the Middle East and North Africa region, 1990-2019. Arch Public Health. 2023;81(1):172. [PMID: 37749704, PMCID: PMC10521494, https://doi.org/10.1186/s13690-023-01188-y].
17. Holmes CJ, McLaughlin A, Farooq T, Awad J, Murray A, Scott R. Outcomes of ocular evisceration and enucleation in the British Armed Forces from Iraq and Afghanistan. Eye (Lond). 2019;33(11):1748-55. [PMID: 31165770, PMCID: PMC7002516, https://doi.org/10.1038/s41433-019-0480-5].
18. Ciftci MD, Selver OB. Sandwich Technique and Amniotic Membrane Transplantation as an Effective Method in Repairing Corneal Perforations. Middle East Afr J Ophthalmol. 2023;30(4):246-9. [PMID: 39959590, PMCID: PMC11823530, https://doi.org/10.4103/meajo.meajo_191_23].
19. Arevalo JF, Garcia RA, Al-Dhibi HA, Sanchez JG, Suarez-Tata L. Update on sympathetic ophthalmia. Middle East Afr J Ophthalmol. 2012;19(1):13-21. [PMID: 22346110, PMCID: PMC3277011, https://doi.org/10.4103/0974-9233.92111].
20. Abdul Al-Redha HAA. Epidemiological Trends of Pediatric Eye Diseases in Iraq: A Cross-Sectional Study. American Journal of Pediatric Medicine and Health Sciences. 2023;3.
21. Hosseini H, Masoumpour M, Keshavarz-Fazl F, Razeghinejad MR, Salouti R, Nowroozzadeh MH. Clinical and epidemiologic characteristics of severe childhood ocular injuries in southern iran. Middle East Afr J Ophthalmol. 2011;18(2):136-40. [PMID: 21731324, PMCID: PMC3119282, https://doi.org/10.4103/0974-9233.80702].
22. Al-Dahan D, Khan AO. Indications for Pediatric Ocular Prosthesis Fitting at a Referral Center in the Middle East. Middle East Afr J Ophthalmol. 2019;26(2):107-9. [PMID: 31543669, PMCID: PMC6737787, https://doi.org/10.4103/meajo.MEAJO_274_18].
23. Mousavi B, Soroush MR, Montazeri A. Quality of life in chemical warfare survivors with ophthalmologic injuries: the first results form Iran Chemical Warfare Victims Health Assessment Study. Health Qual Life Outcomes. 2009;7:2. [PMID: 19152700, PMCID: PMC2647906, https://doi.org/10.1186/1477-7525-7-2].
24. Geiling J, Rosen JM, Edwards RD. Medical costs of war in 2035: long-term care challenges for veterans of Iraq and Afghanistan. Mil Med. 2012;177(11):1235-44. [PMID: 23198496, https://doi.org/10.7205/milmed-d-12-00031].
25. Ramadhan HA, Mardan RE, Fattah FH, Mustafa AM, Habibullah IJ, Mohammed MS, et al. Prevalence of corneal injuries among Halabja populations exposed to chemical weapons: a cross-sectional study. Critical Public Health. 2025;35(1). [https://doi.org/10.1080/09581596.2025.2487206].