ASIDE

ASIDE Gastroenterology

ASIDE GASTROENTEROLOGY

Case Report

Intussusception Caused by a Giant Colonic Lipoma Successfully Treated by Detachable Snare-Assisted Endoscopic Submucosal Dissection

Naoki Ishii[1,*], Masahiro Higuchi[2], Kyohei Oikawa[1], Shinnosuke Noumi[1], Yosuke Murakami[1], Tomoko Katagiri[1]

1-Division of Gastroenterology, Shin-Kuki General Hospital, Kuki, Saitama, Japan
2-Division of Surgery, Shin-Kuki General Hospital, Kuki, Saitama, Japan

ARTICLE INFO

Article history:
Received 22 Oct. 2026
Received in revised form 8 Nov. 2026
Accepted 8 Nov. 2026
Published 25 Nov. 2026

Keywords:
Intussusception
Colonic lipoma
Endoscopic submucosal dissection
Detachable snare
Endoscopic resection

ABSTRACT

Colonic lipomas larger than 4 cm can serve as lead points for colo-colonic intussusception and cause bleeding or obstruction. Although surgical resection has traditionally been preferred, endoscopic techniques such as endoscopic mucosal resection and endoscopic submucosal dissection (ESD) are increasingly reported as safe alternatives in selected patients without ischemia. We describe a 78-year-old man who presented with hematochezia and left lower quadrant discomfort. Contrast-enhanced computed tomography showed a low-density mass causing colo-colonic intussusception from the transverse to the descending colon and preserved colonic wall perfusion with no signs of bowel-wall ischemia. Colonoscopy revealed a giant yellowish submucosal tumor with surface erosions. The base of the tumor was first ligated with a detachable snare, after which ESD was performed distal to the snare using a Hook knife. Preemptive ligation of the tumor base minimized intraprocedural bleeding. The procedure time was 38 minutes. The resected specimen measured 85 × 50 × 25 mm. Histopathology confirmed a benign submucosal lipoma without a malignant component. The intussusception resolved after ESD. During 14 months of follow-up, no recurrence or delayed complications were observed. Detachable snare-assisted ESD can be one of the feasible and potentially useful options for symptomatic giant colonic lipomas causing intussusception.

1. Introduction

Colonic lipomas are the most common benign non-epithelial tumors of the large bowel and usually arise in the submucosa. Most are asymptomatic and discovered incidentally during colonoscopy. However, lesions larger than 2–4 cm frequently become symptomatic, presenting with abdominal pain, altered bowel habits, gastrointestinal bleeding, or intussusception [1, 2]. Adult colo-colonic intussusception is uncommon and almost always has a pathological lead point; lipomas account for a substantial proportion of benign causes [3].

Historically, surgical resection (segmental colectomy or limited resection) was the standard treatment for symptomatic giant lipomas, particularly when intussusception was present, because of concerns regarding ischemia, diagnostic uncertainty, and technical difficulty of endoscopic removal of large fatty lesions [4]. In recent years, advances in endoscopic techniques—including endoscopic mucosal resection (EMR), unroofing, and endoscopic submucosal dissection (ESD)—have enabled successful non-surgical management of selected cases [5–8]. ESD offers the advantage of precise dissection and en bloc resection even for large or broad-based lesions, but it requires specialized skills. Preemptive ligation of the tumor base with a detachable snare can reduce bleeding and facilitate safer dissection [9].

Here we report a case of a giant colonic lipoma causing colo-colonic intussusception and bleeding that was successfully treated by detachable snare-assisted ESD, and we review the literature on endoscopic management of intussuscepting colonic lipomas.

2. Case Report

A 78-year-old man presented with a one-month history of stable left lower quadrant discomfort and new-onset hematochezia. Physical examination of the abdomen was unremarkable. Laboratory tests showed no evidence of ischemia or severe inflammation. Contrast-enhanced computed tomography revealed a well-defined low-density mass extending from the transverse colon to the descending colon, consistent with a lipoma acting as the lead point of colo-colonic intussusception (Figure 1a, b). Contrast-enhanced CT showed preserved colonic wall perfusion, with no signs of bowel-wall ischemia or perforation, and an internally homogeneous lipoma without malignancy. Given the absence of ischemia, the patient's advanced age, and the potential for organ preservation, we

* Corresponding author: Naoki Ishii, Division of Gastroenterology, Shin-Kuki General Hospital, 418-1 Kamihayami, Kuki, Saitama 346-0021, Japan. Email: naoishi0328@gmail.com

Published and owned by PubPorta Publishing LLC. Academic oversight and scholarly guidance are provided by the American Society for Inclusion, Diversity, and Equity in Healthcare (ASIDE). ISSN (Print): 3066-4004, ISSN (Online): 3066-4012. ©2026 The Author(s). This is an open-access article distributed under the terms of the Creative Commons Attribution 4.0 International License (CC BY 4.0). Hosting by ASIDE Journals.

Citation: Ishii N, Higuchi M, Oikawa K, Noumi S, Murakami Y, Katagiri T. Intussusception Caused by a Giant Colonic Lipoma Successfully Treated by Detachable Snare-Assisted Endoscopic Submucosal Dissection. ASIDE GI. 2026;2(4):82-85, doi:10.71079/ASIDE.GI.1125261456

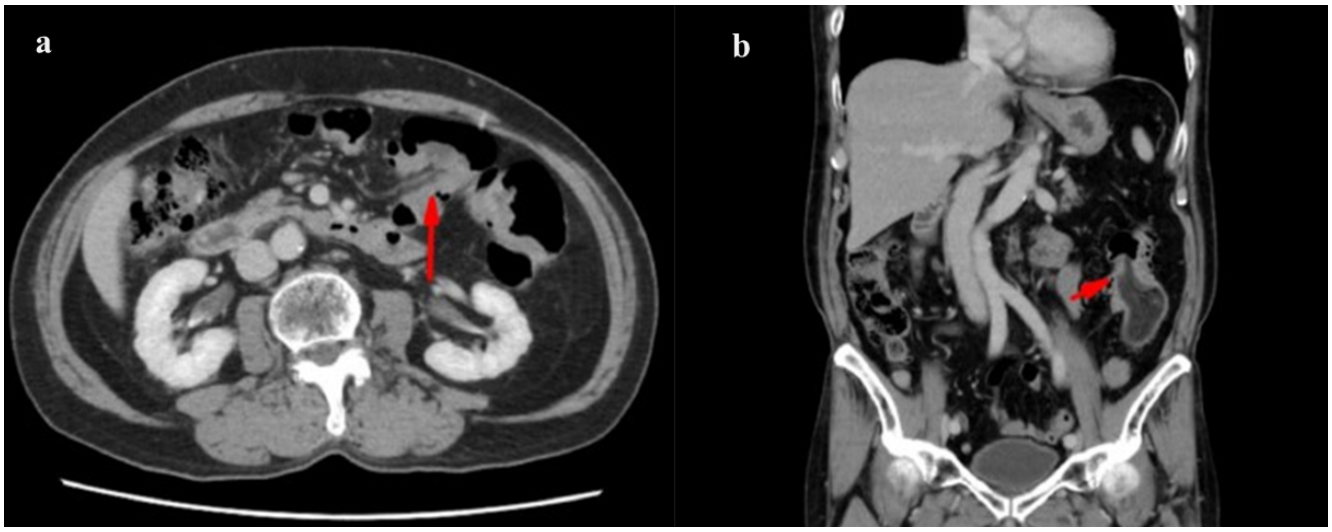

Figure 1: Contrast-enhanced computed tomography images, (a) axial and (b) coronal, showing a well-defined low-density mass serving as the lead point of colo-colonic intussusception from the transverse colon to the descending colon. No signs of bowel-wall ischemia or perforation are present. Red arrows indicate the lipoma (lead point).

elected endoscopic resection with surgical backup available rather than primary colectomy.

Colonoscopy identified a large yellowish pedunculated-type submucosal tumor with surface erosions responsible for the hemorrhage (Figure 2a). Because of its size, conventional snare polypectomy was judged difficult. The base of the tumor was first ligated with a detachable snare (Olympus, Tokyo, Japan) (Figure 2b), and ESD was then performed. After injection of hyaluronate solution, mucosal incision and submucosal dissection were done distal to the snare using a Hook knife (Olympus, Tokyo, Japan) (Figure 2c, d). Intraprocedural bleeding was minimal. Additional clips were placed at the margin to prevent snare dislodgement (Figure 2e). The lesion was resected en bloc. The procedure time was 38 minutes. The resected specimen measured 85 × 50 × 25 mm (Figure 2f). Histopathology confirmed a benign submucosal lipoma without a malignant component. The intussusception resolved after ESD, and the patient recovered smoothly without complications. During 14 months of follow-up, no recurrence or delayed complications were observed.

3. Discussion

Giant colonic lipomas (>4 cm) are clinically important because they can cause intussusception, obstruction, or bleeding [1]. Recent literature demonstrates that endoscopic therapy is feasible and safe in carefully selected patients without ischemia [5–8]. Techniques include EMR (often piecemeal for very large lesions), unroofing, and ESD. A systematic review of large symptomatic colonic lipomas found high clinical remission rates across techniques, although endoscopic resolution rates were higher with EMR, loop-assisted methods, and dissection-based approaches than with simple unroofing [1].

To evaluate the effectiveness and the safety of endoscopic treatments for intussusception caused by colonic lipomas, we performed a rapid review on PubMed using a search term on September 17, 2026: (“Intussusception”[Mesh] OR “Intussusception”[Title/Abstract]) AND (“Lipoma”[Mesh] OR “Lipoma”[Title/Abstract] OR “Lipomas”[Title/Abstract]) AND (“Colon”[Mesh] OR “Colonic Diseases”[Mesh] OR “Colonic Neoplasms”[Mesh] OR colonic[Title/Abstract] OR colon[Title/Abstract]) AND (“Endoscopic Mucosal Resection”[Mesh] OR “Endoscopic Submucosal Dissection”[Title/Abstract] OR ESD[Title/Abstract] OR EMR[Title/Abstract] OR “endoscopic mucosal resection”[Title/Abstract] OR polypectomy[Title/Abstract] OR “polypectomy”[Title/Abstract] OR unroofing[Title/Abstract]). A total of 14 papers were retrieved, and five articles reported endoscopic treatments for intussusception caused by colonic lipoma [5–8, 10]. Two papers were cited from the references of those five articles [11, 12].

Table 1 summarizes published cases of colonic lipomas presenting with intussusception that were treated endoscopically [5–8, 10–12]. Polypectomy, EMR, hybrid unroofing + EMR, and ESD have achieved successful outcomes, supporting a shift toward organ-preserving therapy when ischemia is absent and endoscopic expertise is available.

ESD is particularly useful for giant or broad-based lipomas because it permits precise dissection under direct visualization. Technical challenges include poor electrical conductivity of adipose tissue, instability of the endoscope manipulation, and difficulty retrieving the bulky specimen [8, 12]. Useful strategies include patient repositioning for gravity traction and careful coagulation of vessels within the pseudopedicle [8, 12]. According to our rapid review, Pattarajierapan and Khomvilai and Lin et al. performed ESD for giant lipomas causing intussusception, both without using a detachable snare. In our case, the giant lipoma presented with acute hematochezia

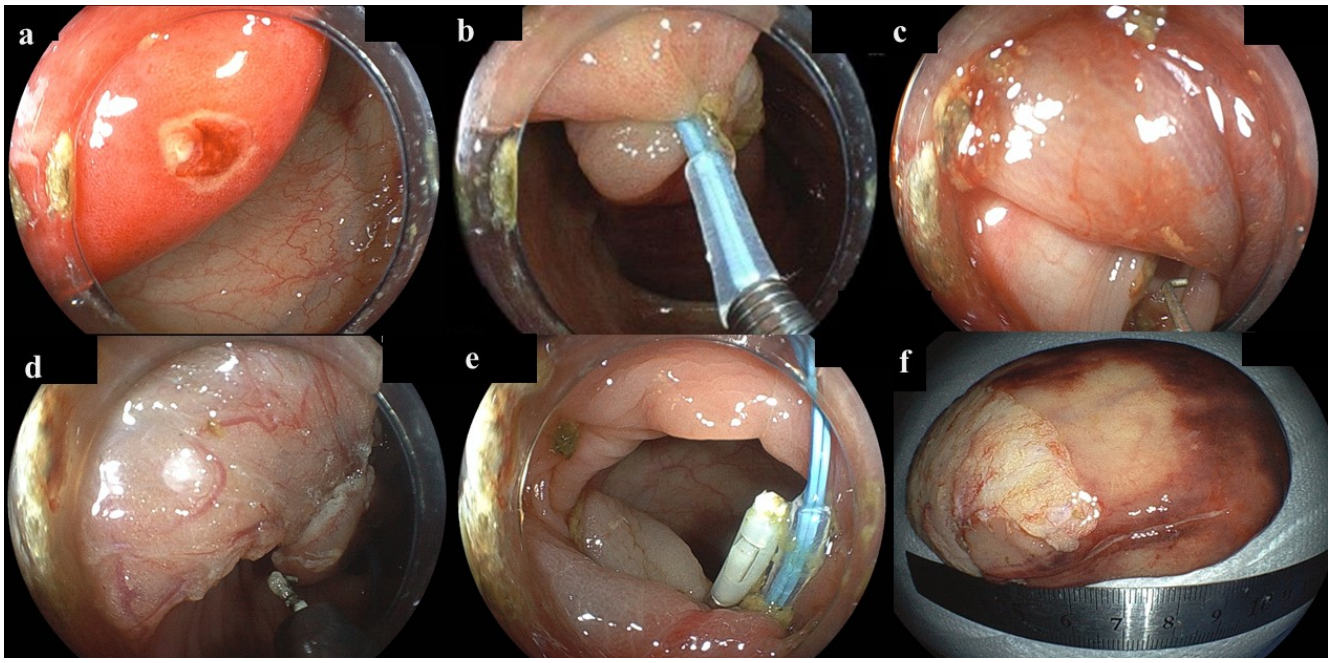

Figure 2: (a) Colonoscopic view of a giant yellowish submucosal tumor with surface erosions responsible for hematochezia. (b) The base of the tumor was ligated with a detachable snare (Olympus, Tokyo, Japan). (c, d) Endoscopic submucosal dissection was performed distal to the snare using a Hook knife (Olympus, Tokyo, Japan). Intraprocedural bleeding was minimal. (e) Additional clips were placed at the margin to prevent snare dislodgement. (f) The resected specimen measured 85 × 50 × 25 mm and was confirmed histologically as a benign submucosal lipoma.

Table 1: Colonic lipomas with intussusception treated by endoscopic treatments.

Author (Year)	Age (years)	Location	Size (cm)	Technique	Outcome	Reference
Kitamura et al. (1990)	44	Transverse–descending	7.5	Polypectomy	Successful	[11]
Geraci et al. (2010)	60	Sigmoid	3.5	Polypectomy	Successful, no recurrence at 6 months	[10]
Schopis and Yang (2019)	22, 37, 46	Sigmoid, splenic flexure, descending	8, 10, 8	Piecemeal EMR	All successful	[5]
Yamamoto et al. (2021)	74	Sigmoid	5.2	Unroofing + EMR	Successful, no recurrence at 1 month	[6]
Pattarajierapan and Khomvilai (2022)	59	Cecum–ascending	8	ESD	Successful	[12]
Eberspacher et al. (2023)	78	Sigmoid	5	EMR	Successful	[7]
Lin et al. (2025)	46	Descending–sigmoid	8	ESD	Successful, no recurrence at 3 months	[8]
Present case	78	Transverse–descending	8.5	Detachable snare + ESD	Successful, no recurrence at 14 months	–

EMR: endoscopic mucosal resection; **ESD:** endoscopic submucosal dissection.

and was therefore considered prone to bleeding during ESD. The use of a detachable snare may have helped avoid massive bleeding during the procedure. To our knowledge, this is the first report of this treatment strategy.

Limitations of endoscopic treatment include the need for experienced operators, longer ESD procedure times, and the theoretical risk of incomplete resection with unroofing. Careful patient selection and preparedness for surgical backup remain essential.

In conclusion, detachable snare-assisted ESD can be one of the feasible and potentially useful options for symptomatic giant colonic lipomas causing intussusception and may spare selected patients from colectomy.

Conflicts of Interest

The authors declare that they have no known competing financial interests or personal relationships that could have appeared to influence the work reported in this article.

Funding Source

This research did not receive any specific grant from funding agencies in the public, commercial, or not-for-profit sectors.

Acknowledgments

The authors have no acknowledgments to declare.

Informed Consent

Informed consent was obtained from the patient.

Institutional Review Board (IRB)

This study has been conducted in accordance with the ethical standards outlined in the 1964 Declaration of Helsinki and its subsequent amendments. Institutional ethics committee approval was not required for this case report.

Large Language Model

English language proofreading and editing support were provided with the assistance of Grok (xAI).

Authors Contribution

NI conceived and designed the study. NI, MH, KO, SN, YM, and TK acquired and interpreted the clinical data. NI drafted the manuscript, and MH, KO, SN, YM, and TK critically revised it for important intellectual content. MH and YM supervised the work. All authors reviewed and approved the final manuscript.

Data Availability

All data relevant to this case are included in the article.

Consent for Publication

Written informed consent for publication of this case report, including the accompanying images, was obtained from the patient.

References

1. Bronswijk M, Vandenbroucke AM, Bossuyt P. Endoscopic treatment of large symptomatic colon lipomas: a systematic review of efficacy and safety. United European Gastroenterol J. 2020;8(10):1147-54. [https://doi.org/10.1177/2050640620948661].
2. Nallamothu G, Adler DG. Large colonic lipomas. Gastroenterol Hepatol (N Y). 2011;7(7):490-2. [PMID: 22298986].
3. Marinis A, Yiallourou A, Samanides L, et al. Intussusception of the bowel in adults: a review. World J Gastroenterol. 2009;15(4):407-11. [https://doi.org/10.3748/wjg.15.407].
4. Hancock BJ, Vajcner A. Lipomas of the colon: a clinicopathologic review. Can J Surg. 1988;31(3):178-81. [PMID: 3284624].
5. Schopis M, Yang J. Endoscopic treatment of intussusception from massive colonic lipomas via endoscopic mucosal resection: a case series. ACG Case Rep J. 2019;6(9):e00177. [https://doi.org/10.14309/crj.0000000000000177].
6. Yamamoto K, Ikeya T, Shiratori Y. Endoscopic unroofing and mucosal resection for a large colonic lipoma with intussusception: an effective hybrid technique. VideoGIE. 2021;6(4):190-2. [https://doi.org/10.1016/j.vgie.2020.11.018].
7. Eberspacher C, Arcieri S, Lauro A, et al. Sizzling fat—curative endoscopic resection of a giant lipoma causing colo-colic intussusception. Dig Dis Sci. 2023;68(11):4123-6. [https://doi.org/10.1007/s10620-023-08087-w].
8. Lin YZ, Chang JS, Chen WC, et al. Endoscopic submucosal dissection as an alternative management for huge colon lipoma with acute intussusception. Endoscopy. 2025;57(S 01):E461-2. [https://doi.org/10.1055/a-2590-7741].
9. Akahoshi K, Kubokawa M, Gibo J, et al. Endoscopic resection using the Clutch Cutter and a detachable snare for large pedunculated colonic polyps. Endoscopy. 2017;49(1):54-8. [https://doi.org/10.1055/s-0042-116023].
10. Geraci G, Pisello F, Arnone E, et al. Endoscopic resection of a large colonic lipoma: case report and review of literature. Case Rep Gastroenterol. 2010;4(1):6-11. [https://doi.org/10.1159/000260053].
11. Kitamura K, Kitagawa S, Mori M, et al. Endoscopic correction of intussusception and removal of a colonic lipoma. Gastrointest Endosc. 1990;36(5):509-11. [https://doi.org/10.1016/S0016-5107(90)71128-5].
12. Pattarajierapan S, Khomvilai S. Endoscopic submucosal dissection of a symptomatic giant colonic lipoma: technical tips for resection and specimen retrieval. VideoGIE. 2022;7(5):190-2. [https://doi.org/10.1016/j.vgie.2022.01.012].